

Case Report / 증례

## A Case Report of Cellulitis Improved after Korean Medical Treatment

Ji-Won Lee · Seung-Ug Hong

Department of Korean Medicine Ophthalmology & Otolaryngology & Dermatology,  
College of Korean Medicine, Dongguk University

### 봉와직염의 한방 치험 1례

이지원<sup>1</sup> · 홍승욱<sup>2</sup>

동국대학교 한방안이비인후피부과(<sup>1</sup>전공의, <sup>2</sup>교수)

### Abstract

**목적** : 본 연구는 한방 치료로 호전된 봉와직염 환자 1례를 보고하고자 한다.

**방법** : 76세 여환으로 봉와직염으로 본원에 입원하여 약 한 달 동안 한방 치료를 시행하였다. 시각 아날로그 척도(VAS), 환측 발의 둘레, 사진 및 염증 수치 등을 평가지표로 삼았다.

**결과** : 퇴원 시 통증, 홍조, 열감, 가려움증과 같은 주관적 증상이 호전되었다. 환측 발의 부종이 감소하였으며, CRP 및 단핵구 수치도 감소하였다. 퇴원 후 약 한 달간의 추적검사 동안 증상이 재발하지 않았다.

**결론** : 봉와직염에 한방 치료를 시행하여 호전을 보인 환자 1례에 대한 보고로, 봉와직염의 한방 치료에 대해 의미 있는 가능성을 제시하였다.

---

**Key words** : Cellulitis; Korean medicine; Case report

## I. Introduction

Cellulitis is a prevalent bacterial skin infection that can potentially have serious consequences. This infection targets the middle skin layer(dermis) as well as the underlying tissues, occasionally extending to the muscle beneath the skin<sup>1)</sup>.

The infection happens when a break in the skin allows bacteria to enter. There's evidence indicating that the existence of fungal foot infections like tinea pedis and toenail onychomycosis can increase the risk of cellulitis within the lower limb. Moreover, factors such as a history of peripheral vascular disease and the utilization of corticosteroid medications or other immune-suppressing drugs are also recognized as risk factors for the development of cellulitis<sup>2,3)</sup>.

Cellulitis typically resolves within 7 to 10 days with the use of antibiotics<sup>4)</sup>. However, people with fungal foot infections, particularly those who have diabetes, may experience recurrent cellulitis<sup>3)</sup>. When cellulitis is left untreated or if the treatment is ineffective, it can lead to various complications such as lymphangitis, sepsis, osteomyelitis, endocarditis, meningitis, shock, and more<sup>5)</sup>. To address the infection and alleviate cellulitis severity, treatment should consider immune stimulatory activity. This immune support is crucial for promoting tissue repair and regulating inflammation<sup>6)</sup>.

Sodokum, first documented in the Ming

Corresponding author : Seung-Ug Hong, Department of Korean Medicine Ophthalmology & Otolaryngology & Dermatology, Dongguk University, 27, Dongguk-ro, Ilsandong-gu, Goyang-si, Gyeonggi-do, Republic of Korea.  
(Tel : 031-961-9085, E-mail : heenthstu@duih.org)

• Received 2023/10/7 • Revised 2023/10/20 • Accepted 2023/10/27

Dynasty's 'Uigamseo', has been used in the treatment of rashes. Some studies have shown its antibacterial effects against various skin pathogens, antioxidant properties, and anticancer effects<sup>7)</sup>. Sipjeondaebo-tang, Samul-tang plus Sagunja-tang, has immune stimulatory activity, showing splenocyte proliferation and macrophage proliferation<sup>8)</sup>.

Besides the cases reported by Lee et al.<sup>9)</sup>, Choi et al.<sup>10)</sup>, and others<sup>11)</sup>, there are limited case reports on Korean medical treatment for cellulitis. We confirmed symptom improvement in the patient with cellulitis through enhanced local immunity with the combination of Sodokum and Sipjeondaebo-tang.

This case report describes Korean medical treatment for cellulitis.

## II. Objects & Methods

### 1. Objects

We studied one patient who developed cellulitis after sustaining toe wounds caused by a foot fungus. The patient has been fully informed and has given consent for the use of their information in publishing this paper.

### 2. Evaluation

#### 1) Visual analogue scale(VAS)

The Visual Analog Scale(VAS) is a measurement tool used to assess subjective experiences, primarily pain, discomfort, or other subjective sensations. The VAS was utilized to evaluate the degree of discomfort perceived by the patient,

including pain, redness, heat, and itching. The score ranged from 0 to 10, with 0 indicating no sensation or discomfort and 10 indicating the most severe or intense experience.

## 2) The circumference of the left foot

To assess edema, we measured the circumference of the left foot passing through the 太衝(LR3) acupuncture point, which served as the central point of the lesions, in centimeters.

## 3) Photo shoot

We obtained the patient's prior consent to document changes in the skin lesions through photographs taken from June 29, 2023, the admission date, to August 30, 2023, the last clinic visit date.

## 4) Biochemical and hematological blood tests

To assess inflammation markers, we conducted blood tests three times throughout the hospitalization.

## 3. Ethical approval

This study was conducted with approval for exemption from review by Ilsan oriental hospital, Dongguk university(approval number : DUIOH 2023-09-006).

# III. Case

1. Patient : ○○○(F/76/Height 153cm/Body weight 60.3kg)

2. Treatment period : 2023.6.28.-2023.8.30

(Admission : 2023.6.29-2023.7.24, Outpatient clinic visit dates : 2023.8.2, 2023.8.30)

3. Chief complaint : Pain, redness, heat, itching, and swelling of the left foot

4. Onset : 2023.6.7

5. Past history : Left tinea pedis & unguium

6. Family history : None of specific

7. Social history : None of specific

## 8. Present illness

On June 7, 2023, a 76-year-old female patient experienced sudden pain, redness, heat, and swelling in her left foot, along with a preexisting condition of tinea pedis and unguium. She sought medical attention at the internal medicine department on June 14, 2023, where she was diagnosed with cellulitis. She took cephalosporin antibiotics(Suprax capsule) for 7 days. On June 28, 2023, she began Korean medical treatment for her condition.

## 9. An initial opinion

1) Digestive system : Normal

2) Respiratory system : Normal

3) Sleep : Normal(8hrs/day)

4) Defecation : 1 time/day

5) Voiding : Normal

6) Tongue diagnosis : A pale tongue with thin white coating

7) Pulse diagnosis : A pulse that is thready, soft, deep and weak

## 10. Treatment

### 1) Herbal medicine

The patient took 3 times a day during June 29, 2023 to July 24, 2023. The same medicine was prescribed for 10 days at discharge(Table 1).

Table 1. Prescription of Sodokum Plus Sipjeondaebo-tang

Herbal name	Scientific name	Dose (g)
牛蒡子	<i>Arctii Semen</i>	8
荊芥	<i>Schizonepetae Spica</i>	4
防風	<i>Peucedani Radix</i>	2
人參	<i>Ginseng Radix Alba</i>	5
白朮	<i>Atractylodes Rhizome Alba</i>	5
白茯苓	<i>Hoelen</i>	5
甘草	<i>Glycyrrhizae Radix et Rhizoma</i>	5
熟地黃	<i>Rehmanniae Radix Preparata</i>	5
芍藥	<i>Paeoniae Radix</i>	5
川芎	<i>Cnidii Rhizoma</i>	5
當歸	<i>Angelicae Gigantis Radix</i>	5
黃芪	<i>Astragali Radix</i>	4
肉桂	<i>Cinnamomi Cortex Spissus</i>	4
Total		62

### 2) External application treatment

We instructed the patient to use Chisun solution(containing *Hibisci Cortex*(木槿皮), Salicylic acid, etc., produced by Hani External Therapy Association) to relieve symptoms of athlete's foot. Additionally, for redness and heat relief, we recommended the application of Sambaekihwan-go(manufactured by Hani External Therapy Association) to the affected area as needed. During the hospitalization period, a daily wet dressing was applied to the left foot for 20 minutes each day using an external prescription of our hospital(Table 2).

Upon discharge, the patient received instructions on wet dressing procedures and continued the regimen at home using the same external prescription for a consecutive 15 days after discharge.

Table 2. An External Prescription

Herbal name	Scientific name	Dose (g)
樺皮	<i>Betulae Cortex</i>	10
梔子	<i>Gardeniae Fructus</i>	15
黃連	<i>Coptidis Rhizoma</i>	10
苦參	<i>Sophorae Radix</i>	15
白鮮皮	<i>Dictamni Radicis Cortex</i>	10
Total		60

### 3) Acupuncture treatment

The acupuncture needles were standardized stainless steel, 0.25×40mm, and disposable (manufactured by Boryung, a Korean Eastern acupuncture equipment manufacturer). Acupuncture was administered at the affected area of the left foot for 15 minutes once a day during the hospitalization period. The depth of the acupuncture needle insertion was approximately 3-5 millimeters.

### 4) Other treatments

Carbon-arc-light was used with acupuncture treatment.

## 11. Clinical progression

### 1) VAS

At admission, the patient reported throbbing pain, particularly around the left ankle, with a VAS score of 4. Due to this pain, walking for more than 5 minutes without assistance from a

monocane was not possible. Redness, heat, and itching sensations were rated as VAS 5, VAS 3, and VAS 3, respectively. Standing or moving exacerbated the redness, eventually causing the left foot to turn black.

Upon discharge, the pain decreased to approximately VAS 1, allowing the patient to walk for around 20 minutes without monocane assistance. Both redness, heat, and itching sensations significantly decreased to VAS 2.

At the outpatient follow-up on August 2, 2023, subjective symptoms, including pain, redness, heat, and itching, reduced to VAS 1. In the final follow-up on August 30, 2023, not only was there no recurrence of symptoms, but all symptoms were almost completely resolved to the point of the patient enjoying hiking(Fig. 1).

## 2) The circumference of the left foot

It decreased by approximately 10%, from 24.6 cm at admission to 22.8cm at discharge(Fig. 2).

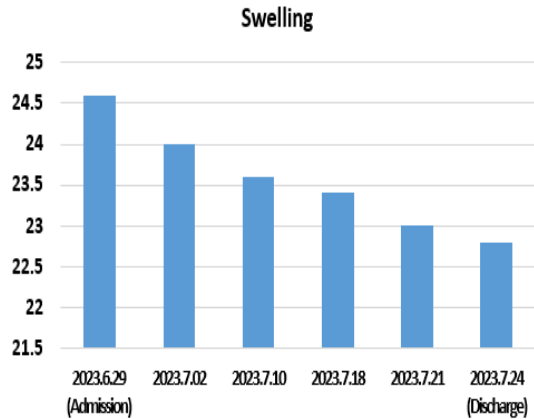


Fig. 2. Change in Circumference

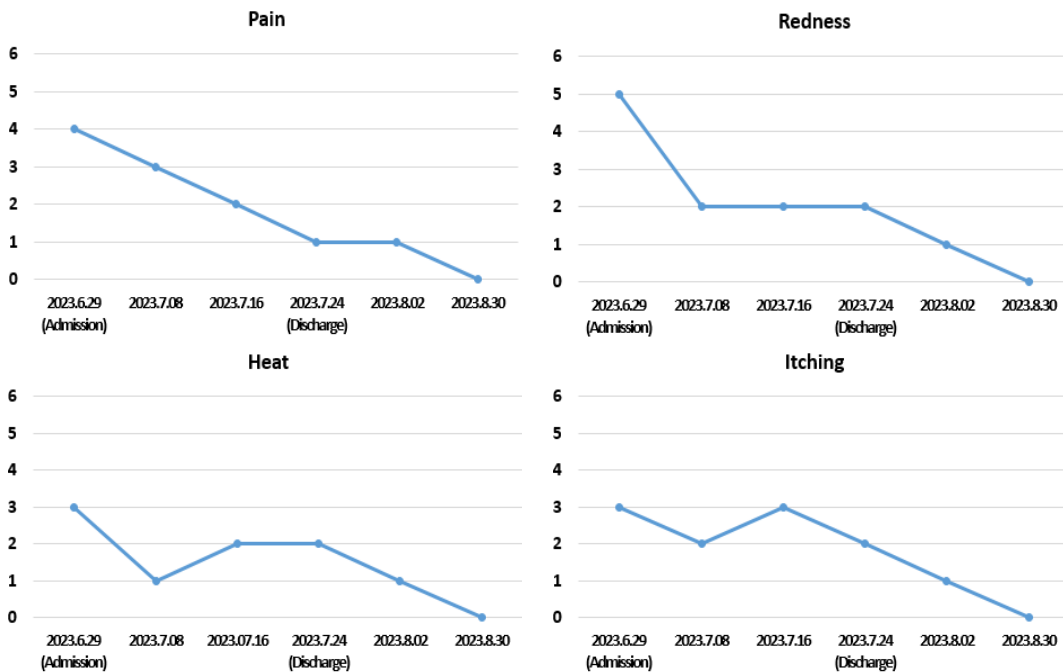


Fig. 1. Change in VAS

### 3) Photo shoot

Throughout the hospitalization, the skin exhibited a pattern of epidermal shedding as part of the regeneration process. The lateral malleolus was the site where pain and redness were most severe. Approximately 10 days after discharge, the skin color had further lightened, and in the final outpatient follow-up, it had almost returned to normal compared to the unaffected side(Fig. 3).

### 4) Biochemical and hematological blood tests

In the blood test conducted immediately after admission, the CRP level was elevated at 0.69mg/dL, surpassing the normal range of 0-0.50mg/dL. However, in the blood test performed five days after admission, the CRP level significantly decreased to 0.16mg/dL. Looking at the complete blood cell count results, during the early hospitalization period, the monocyte level

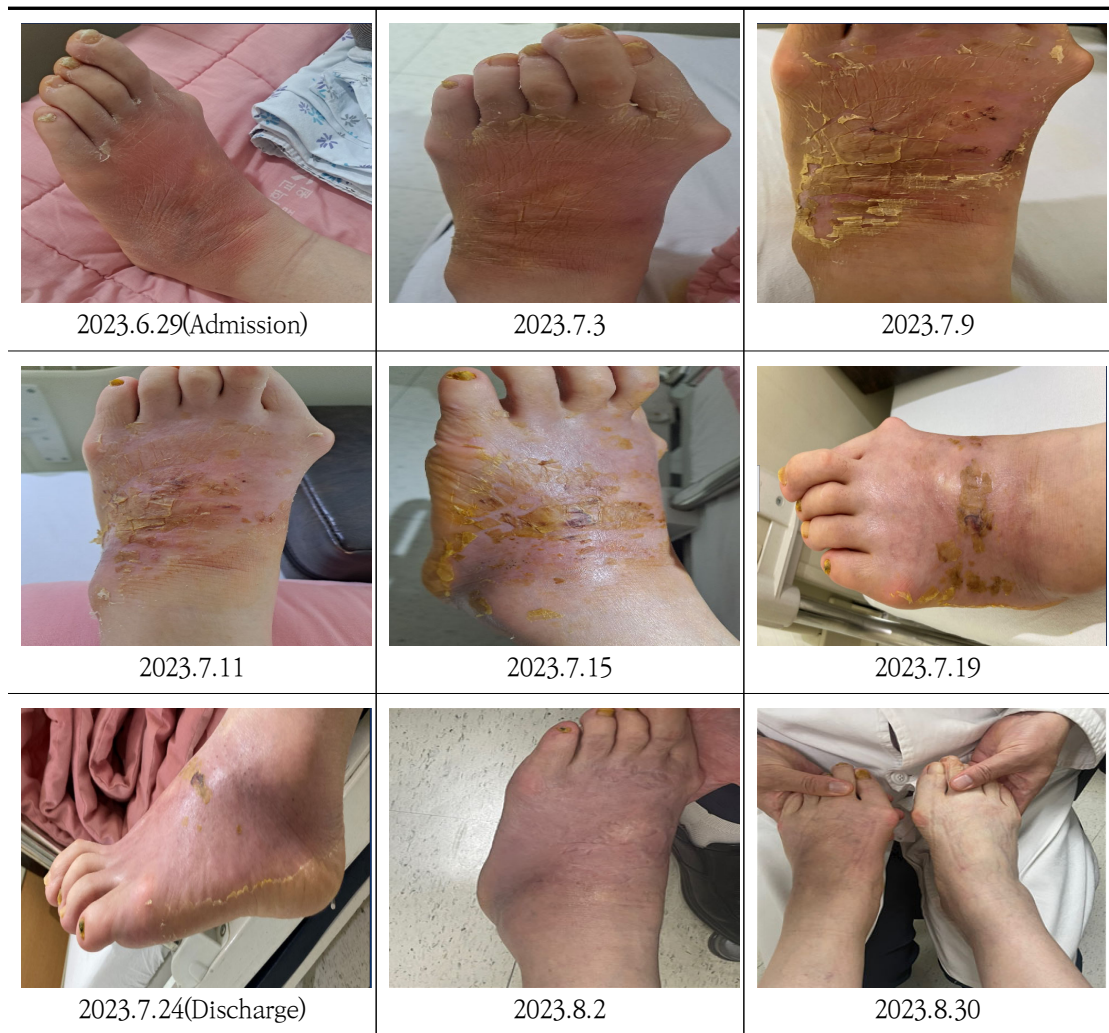

Fig. 3. Change of Skin Lesions

slightly exceeded the normal range of 2-9%, but it returned to within the normal range on the third blood test(Table 3).

#### IV. Discussion

Cellulitis occurs most frequently in the lower extremities and usually unilateral<sup>2)</sup>. Clinically, patients experience redness, swelling, increased temperature, and heightened sensitivity in their skin<sup>1)</sup>. The most recent guideline from The Infectious Disease Society of America(IDSA) on skin and soft tissue infections states that most cases of cellulitis are due to streptococci, often *Streptococcus pyogenes*, but also groups B, C, or G. *S. aureus* is also noted to cause cellulitis, especially when associated with furuncles, carbuncles, or abscesses<sup>4)</sup>.

Unfortunately, there is no definitive or reliable diagnostic method for cellulitis. Routine biochemical and hematological blood tests, as well as blood cultures, lack specificity in confirming the diagnosis<sup>13)</sup>. Recently, there has

been a recognition that change in peripheral blood leukocyte ratios serves as a simple, rapid, and novel inflammation parameter for several diseases. Specifically, blood monocytes offer insight into the systemic immune response, from production to tissue recruitment, reflecting the impact of infection on the host<sup>12,14)</sup>.

Skin infections are the most common cause of lymphangitis. Lymphangitis can occur in the setting of normal lymphatic channels with acute infection, damaged lymphatic channels, or anatomic abnormalities. Acute lymphangitis may occur in the setting of skin abrasion with infection at a distal site, such as interdigital dermatophyte infection or cellulitis or erysipelas of the lower leg. Lymphatic damage and anatomic abnormalities can result in tissue protein and fluid accumulation, leading to nonpitting lymphedema with induration and predisposing to invasion of microorganisms. Particularly, when standing, the effects of gravity can contribute to heightened fluid buildup and impaired blood circulation around the inflamed area, potentially exacerbating pain and

Table 3. The Results of Blood Tests

Blood tests		2023.6.30	2023.7.4	2023.7.17
Chemistry	CRP(mg/dl)	0.69	0.16	0.10
	WBC( $\times 10^3/\mu l$ )	5.23	5.62	5.53
	RBC( $\times 10^6/\mu l$ )	4.42	4.47	4.41
	Hb(g/dl)	12.6	12.8	12.6
	Hct(%)	39.8	39.9	39.4
Hematology	Platelet( $\times 10^3/\mu l$ )	256	262	237
	Neutrophil(%)	61.3	50.9	54.7
	Lymphocyte(%)	26.8	37.0	34.0
	Monocyte(%)	9.4	9.6	9.0
	ANC	3206	2861	3025

redness<sup>15)</sup>.

To evaluate the results, we checked not only whether symptoms improved and whether there was a recurrence but also inflammatory markers through blood tests and observed lesion changes in photographs. The patient, experiencing heightened pain upon standing and moving due to infection extending to the underlying tissues, was unable to walk for more than 5 minutes without assistance from a monocane upon admission. If standing or moving persisted beyond 10 seconds, pain and redness intensified, eventually leading to the skin of the left foot turning black. Additionally, the circumference of the affected foot was 24.6cm. However, at the time of discharge, the patient could walk for approximately 20 minutes without monocane assistance, and the circumference had reduced to 22.8cm. We also confirmed that the patient exhibited a decrease in both CRP and monocyte levels after hospitalization. At the one-month follow-up after discharge, the patient reported no issues with independent walking and had sufficiently recovered to enjoy hiking.

This case signifies a significant outcome as it validates improvement in both subjective and objective symptoms, including edema circumference and hematological measures, following 26 days of hospitalization treatment. During the two outpatient follow-up visits, there was no recurrence of symptoms, and all symptoms were almost completely resolved. This is a meaningful result as it indicates the disappearance of subjective symptoms and no recurrence after only Korean medical treatment, which lasted for about one month.

In our study, 'Sodokum plus Sipjeondaebo-tang' was used as herbal medicine treatment based on the principle of 'strengthening the body's resistance to eliminate pathogenic factors (扶正祛邪)'. When inflammation arises in the body, the immune system expends significant energy combating the infectious agent, leading to a decline in overall health and vitality. Consequently, the treatment of infectious diseases should not only focus on eliminating the pathogen but also consider the restoration of the patient's energy levels<sup>6)</sup>.

*Arctii Semen*(牛蒡子) and *Peucedani Radix*(防風), the components of Sodokum, are known for dispelling wind and heat. Additionally, *Arctii Semen* and *Schizonepetae Spica*(荊芥) detoxify and clear up rashes to prevent complications<sup>7)</sup>. Sipjeondaebo-tang is a commonly prescribed herbal formula in Korea, Japan, and China. It effectively addresses both qi and blood deficiency syndromes by harmonizing Yin and Yang. Widely employed in the treatment of chronic illnesses, Sipjeondaebo-tang restores physiological function and boosts immunity. Previous studies highlight diverse biological properties of Sipjeondaebo-tang, including anti-cancer, anti-inflammatory, gastric protective, and immune cell activation effects<sup>8)</sup>.

In this case, the patient exhibited no significant issues with sleep or appetite but experienced reduced energy due to infectious diseases, presenting with a pale tongue and thin white coating, along with a thready, soft, deep, and weak pulse. The diagnosis indicated both qi and blood deficiency syndromes resulting from the pathogen, leading to the prescription of this



herbal medicine.

Examining the external application treatment utilized in this study, the Chisun solution, featuring *Hibisci Cortex* as its primary component, is renowned for its outstanding efficacy in athlete's foot treatment with excellent anti-ringworm and anti-inflammatory effects<sup>16)</sup>. Sambaekihwan-go is comprised of powdered *Angelicae Dahuricae Radix*(白芷), *Bletillae Rhizoma*(白芨), *Alunitum Siccus*(枯白礬), *Sulphur*(硫黃), and *Phellodendri Cortex*(黃柏). It is known for its heat-clearing properties and itching reduction, proving effective against various bacterial and fungal skin diseases<sup>17)</sup>. Wet dressing contributes to a cooling effect by absorbing the skin's heat, thereby aiding in the reduction of inflammation. Simultaneously, it alleviates itching sensations stemming from the shedding epidermis during the wound recovery process<sup>17,18)</sup>.

We conducted acupuncture treatment on affected sites for the anti-inflammatory mechanism through microtrauma. The acupuncture stimulus induces local microtrauma, triggering the activation of neuro-immune reflexes. These include mast cell involvement and the release of vasoactive substances such as cGRP, histamine, SP, adenosine, prostaglandin, bradykinin, etc. This leads to vasodilation in small vessels, increased blood flow, and the initiation of local inflammatory and anti-inflammatory responses<sup>19)</sup>. In addition, carbon-arc-light irradiation treatment was performed to aid in wound regeneration, metabolism, and swelling absorption during acupuncture treatment<sup>20)</sup>.

This case highlights the potential effectiveness of Korean medicine treatment in alleviating cellulitis, suggesting positive outcomes when employing Korean medicine for cellulitis symptoms.

Research on cellulitis within the realm of Korean medicine is not only confined to case reports but is also notably scarce in quantity. Therefore, further research is imperative. This case report holds significance as it demonstrated improvements solely through Korean medicine interventions, including herbal medicine, external applications, and acupuncture.

However, deriving broad conclusions about the effectiveness of Korean medicine treatment for cellulitis from this single case is challenging. Anticipating more cases in the future, we hope to see elevated research, including experimental considerations and randomized controlled trials(RCTs), to enhance the level of evidence for treatment.

## V. Conclusion

In this study, we present a case of cellulitis treated with Korean medicine, highlighting the resolution of subjective symptoms and the absence of recurrence. This case can serve as a foundational reference for future Korean medical treatment and research of cellulitis.

## ORCID

Ji-Won Lee

(<https://orcid.org/0000-0003-4947-7427>)

Seung-Ug Hong  
(<https://orcid.org/0000-0002-6228-3312>)

## References

- Gunderson CG, Martinello RA. A systematic review of bacteremias in cellulitis and erysipelas. *J Infect.* 2012;64(2):148-55.
- Norazirah MN, Khor IS, Adawiyah J, Tamil AM, Azmawati MN. The risk factors of lower limb cellulitis: A case-control study in a tertiary centre. *Malays Fam Physician.* 2020;15(1):23-9.
- Zacay G, Hershkowitz SF, Heymann AD. Glycemic Control and Risk of Cellulitis. *Diabetes Care.* 2021;44(2):367-72.
- Stevens DL, Bisno AL, Chambers HF, Dellinger EP, Goldstein EJ, Gorbach SL, et al. Practice guidelines for the diagnosis and management of skin and soft tissue infections: 2014 update by the infectious diseases society of America. *Clin Infect Dis.* 2014;59(2):147-59.
- Ren Z, Silverberg JJ. Burden, risk factors, and infectious complications of cellulitis and erysipelas in US adults and children in the emergency department setting. *J Am Acad Dermatol.* 2021;84(5):1496-503.
- Eming SA, Wynn TA, Martin P. Inflammation and metabolism in tissue repair and regeneration. *Science.* 2017;356(6342):1026-30.
- Yoon JM, Kim DI, Lee JH, Han SJ, Kim HE, Kim HJ, et al. Study on Anti-oxidant and Anti-inflammatory Activity of Eggplant-cheongyeolsodokum. *J Soc Cosmet Scientists Korea.* 2017;43(2):125-35.
- Lee HY, Ha HK, Jung DY, Lee NH, Shin HK. Immuno stimulatory activities of Samul-tang, Sagunja-tang, Pamul-tang and Sipjeondaebotang in vitro. *J of Oriental Neuropsychiatry.* 2010;21(4):41-51.
- Lee SK, Moon MH, Cho YK, Lee JS, Nam SK, Lee SH, et al. Clinical Study on 1 Case of Patient with Cellulitis Treated by Oriental and Western Medicine Simultaneously. *JPPKM.* 2007;21(1):333-7.
- Choi YJ, Bae HJ, Hong SH. A Case Report of patient underwent Debridement caused by Cellulitis improved with Gamisunbangwhalmyung-Eum. *J Korean Med Ophthalmol Otolaryngol Dermatol.* 2013;26(4):111-8.
- Lee JH, Cho SE, Woo YM, Kim YH. A case report on cellulitis treated with therapeutic intervention of oriental medicine. *Korean J Orient Int Med.* 2001;22(3):483-8.
- Ince N, Güçlü E, Sungur MA, Karabay O. Evaluation of neutrophil to lymphocyte ratio, platelet to lymphocyte ratio, and lymphocyte to monocyte ratio in patients with cellulitis. *Rev Assoc Med Bras(1992).* 2020;66(8):1077-81.
- Sullivan T, Barra E. Diagnosis and management of cellulitis. *Clin Med.* 2018;18(2):160-3.
- Martinez FO, Combes TW, Orsenigo F, Gordon S. Monocyte activation in systemic Covid-19 infection: Assay and rationale. *EBioMedicine.* 2020;59:102964.
- Simon MS, Cody RL. Cellulitis after axillary lymph node dissection for carcinoma of the

- breast. Am J Med. 1992;93:543.
16. Jang YW, Jung JY, Lee IK, Kang SY, Yun BS. Nonanoic Acid, an Antifungal Compound from Hibiscus syriacus Ggoma. Mycobiology. 2012;40(2):145,146.
  17. Jung ARNR, Hong SU. A Case of Atopic Dermatitis with Nummular Eczema. J Korean Med Ophthalmol Otolaryngol Dermatol. 2006;19(2):296-303.
  18. Shin SH, Kim MB, Byun SM, Lee HS, Park SG, Ko WS, et al. A Review on External Treatment for Atopic Dermatitis in Korean Journals. J Korean Med Ophthalmol Otolaryngol Dermatol. 2008;21(2):80-93.
  19. Jin BX, Jin LL, Jin GY. The anti-inflammatory effect of acupuncture and its significance in analgesia. WJAM. 2019;29(1):1-6.
  20. Lim HW, Yoon CJ, Kim JH. A case of decubitus ulcer treated with carbon-arc-light treatment. J Int Korean Med. 2009;30(110):203-7.